

Endomyocardial fibrosis causing right intraventricular gradient and obliteration

Sağ ventrikül içi basınç gradiyentine ve obliterasyona neden olan endomiyokardiyal fibrozis

Gulten Tacoy, M.D., Yusuf Tavli, M.D., Adnan Abaci, M.D.

Gazi University, Faculty of Medicine, Department of Cardiology, Ankara

Endomyocardial fibrosis is a cause of restrictive cardiomyopathy and it generally occurs in tropical regions more commonly affecting children and young adults. A 19 year old male patient presented with edema in the lower extremities and fatigue. Transthoracic echocardiography showed dilated right heart chambers, restrictive physiology in the left ventricle, and increased tissue growth in the right ventricle which causes a 60 mmHg gradient and obliteration. Magnetic resonance imaging confirmed the presence of increased tissue formation in the right ventricular inflow region. Surgical resection was not considered taking into account the functional capacity of the patient (class II), disappearance of symptoms following medical treatment, and high risk for perioperative mortality. The presented case may arouse interest in that it increased tissue growth in the right ventricle, leading to an incorrect diagnosis, at another center, as idiopathic pulmonary hypertension.

Key words: Cardiomyopathy, restrictive; echocardiography; endomyocardial fibrosis; magnetic resonance imaging.

Endomyocardial fibrosis (EMF), which was first described in Uganda in 1947^[1], is one of the most common causes of restrictive cardiomyopathy in tropical regions and is rarely seen in Turkey. We present here a patient who visited with a clinical picture of rightsided heart failure and restrictive cardiomyopathy due to EMF with involvement of both ventricles, but which was more prominent in the right ventricle.

CASE REPORT

A 19 year old male patient presented with complaints of edema in the lower extremities for the past 8 months and fatigue. The patient was diagnosed with idiopathic pulmonary arterial hypertension (IPAH) based on the echocardiograms showing a systolic pulmo-

Restriktif kardiyomiyopatiye neden olan endomiyokardiyal fibrozis tropik iklimlerde sık gözlenir ve genellikle çocuklarda ve genç erişkinlerde görülür. Bacaklarda şişlik ve çabuk yorulma yakınması ile başvuran 19 yaşındaki erkek hastanın transtorasik ekokardiyografisinde sağ kalp boyutlarında genişleme, sol ventrikülde restriktif akım örneği, sağ ventrikül içinde 60 mmHg gradiyent yaratan ve obliterasyona neden olan doku yoğunlaşması saptandı ve manyetik rezonans görüntülemeye sağ ventrikül giriş bölgesinde doku artışı izlendi. Hastanın sınıf II düzeyindeki fonksiyonel kapasitesi, medikal tedaviye iyi yanıt alınması ve ameliyat mortalitesi riskinin yüksek olması nedeniyle cerrahi rezeksiyon düşünülmeydi. Sunulan olgunun en ilginç noktası, sağ ventrikül giriş bölgesindeki doku yoğunluğunun obstrüksiyona neden olarak sağ ventrikül içinde basınç farkı yaratması ve bu durumun başka bir merkezde idiyopatik pulmoner hipertansiyon olarak değerlendirilmesine yol açmış olmasıdır.

Anahtar sözcükler: Kardiyomiyopati, restriktif; ekokardiyografi; endomiyokardiyal fibrozis; manyetik rezonans görüntüleme.

nary artery pressure of 85 mmHg. He was then referred to our hospital for further consultation and treatment. The patient did not have any history of hypertension, diabetes mellitus, cigarette smoking, and familial cardiac disease. With a classII functional capacity at presentation, his physical examination demonstrated a blood pressure of 100/60 mmHg, regular pulse rate of 60/min. The cardiovascular examination with venous distention in the neck also revealed a 3/6 systolic ejection murmur best heard at the pulmonary focus, and spreading to other foci. Liver was palpated at 2 cm below the costal margin, presenting with ascites and pretibial edema (++)/++). His complete blood count and biochemical test results were normal; there was no finding suggesting increased eosinophil count. Electrocar-

Received: 30.12.2008 Accepted: 12.03.2009

Corresponding address: Dr. Gülten Taçoy. Gazi Üniversitesi Tıp Fakültesi, Kardiyoloji Anabilim Dalı, 06500 Beşevler, Ankara.
Tel: +90 - 312 - 202 56 23 e-mail: gtacoy@gmail.com

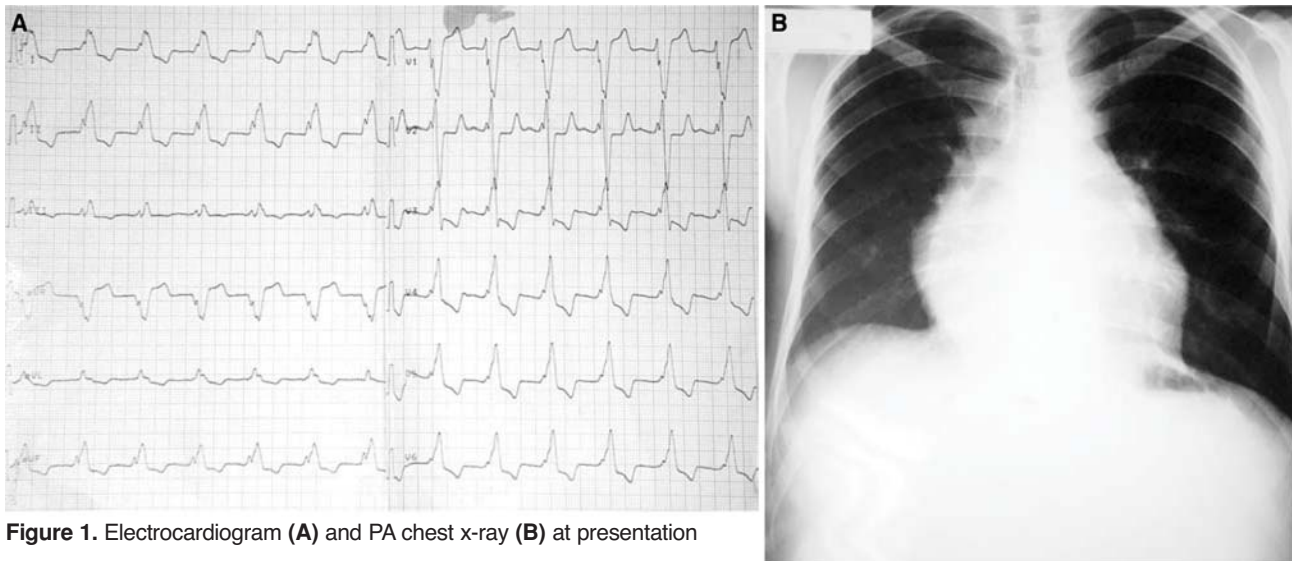


Figure 1. Electrocardiogram (A) and PA chest x-ray (B) at presentation

diography showed regular rhythm with left bundle branch block pattern along with advanced level of QRS widening (220 msec) (Figure 1a). A PA chest x-ray also showed a faint aortic curve, prominent pulmonary conus as well as decreased pulmonary vascularization and a heart apex which was slightly repositioned upwards in favor of right ventricular hypertrophy (Figure 1b). Transthoracic echocardiography demonstrated normal size of left ventricular space, dilated atriums with more prominence on the right side, and restrictive mitral flow in the left ventricle. The peak systolic pressure in the right ventricle was 90 mmHg through a grade II tricuspid regurgitation. Increased fibrous tissue in the right ventricle and turbulent flow in the right ventricular inflow region, leading to a 60 mmHg gradient were also observed. The maximum systolic pulmonary artery pressure was considered to be 30 mmHg taking into consideration the gradient in the right ventricle. In addition, echocardiography revealed increased wall thickness in both ventricles with marked involvement of the right ventricle (Figure 2). Tissue density which led to obliteration in the right ventricle was also de-

monstrated by transesophageal echocardiography. Congenital heart pathologies were excluded by transthoracic and transesophageal echocardiography, while MRI confirmed the present findings with increased tissue density in the right ventricle and significantly dilated right atrium (Figure 3). The right ventricular pressure was measured as 92/13/20 mmHg (systolic/diastolic/enddiastolic) during right heart catheterization. However, measurement of pulmonary artery pressure was discontinued when the patient developed monomorphic ventricular tachycardia while advancing the catheter through fibrotic tissue which led to narrowness in the right ventricle. Right ventriculography also demonstrated narrowness in the right ventricle. Infiltrative diseases, storage diseases, conditions leading to endocardial involvement (history of hypereosinophilic syndrome, drug use, and radiation, etc.), familial cardiomyopathy, collagenous tissue diseases and diabetes mellitus, which may be among the reasons for restrictive cardiomyopathy were excluded by transthoracic and transesophageal echocardiography, MRI, upper abdominal ultrasonography and laboratory analysis.

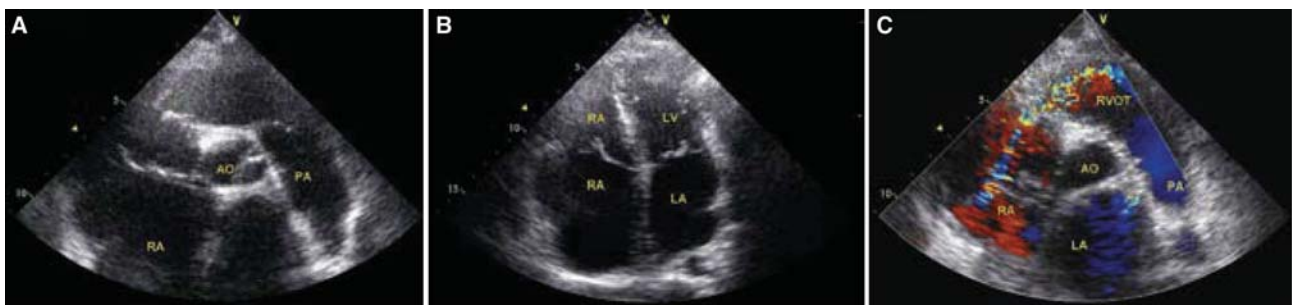

Figure 2. (A) Transthoracic echocardiographic short-axis images showing increased tissue density in the right ventricle and (B) significant dilatation in the right heart chambers. (C) Color Doppler image suggesting narrowness in the right ventricle due to increased tissue density.

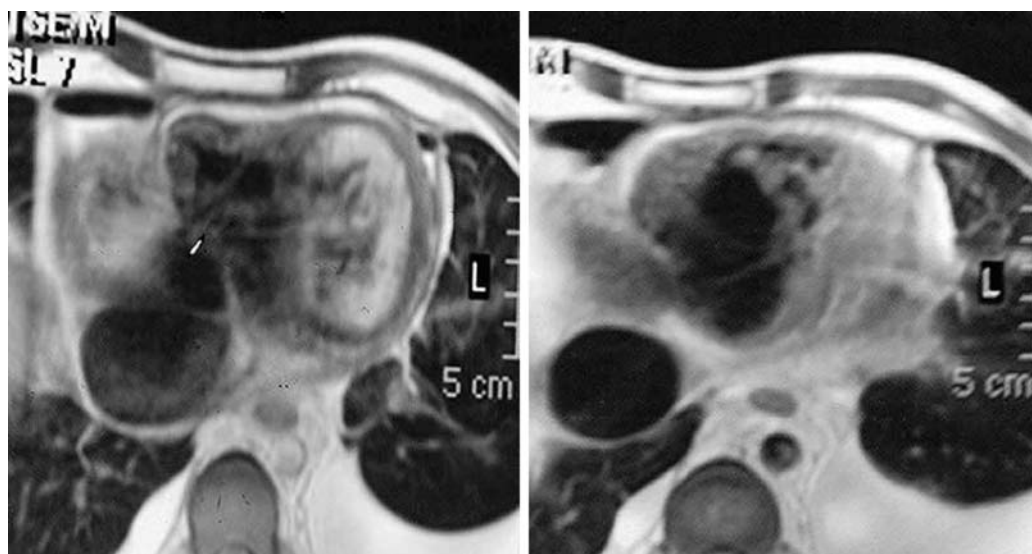


Figure 3. MRI sections showing increased tissue density in the right ventricle.

The patient was diagnosed with restrictive cardiomyopathy associated with EMF based on echocardiography and MRI findings as well as clinical characteristics of the patient. Despite echocardiographic and MRI findings suggesting restrictive cardiomyopathy, endomyocardial biopsy was initially considered to confirm the diagnosis. However, the procedure was not performed due to the triggering risk for ventricular tachycardia observed during catheterization. The patient's symptoms remarkably regressed by the treatment with loop diuretics, spironolactone and angiotensin converting enzyme inhibitors. The patient was scheduled for medical followup taking into account the functional capacity of the patient (class II), disappearance of symptoms following medical treatment, and high risk for perioperative mortality.

DISCUSSION

Endomyocardial fibrosis is an idiopathic disease seen in tropical regions and which leads to restrictive cardiomyopathy.^[2,4] EMF which is rarely seen in developed countries is more common in young women and children.^[5,6] It is the most common cause of restrictive cardiomyopathy in tropical regions. Infectious, inflammatory and dietary causes as well as eosinophilic toxicity are the other factors which play a role in the pathophysiology of the disease.^[2,3] Endomyocardial fibrosis predominantly involves the inflow region of the ventricles; valvular regurgitations may be seen in the clinical presentation when atrioventricular valves are involved. Biventricular disease is seen in 50% of the patients, while left ventricular and right ventricular involvement is seen in 40% and %10 of the patients, res-

pectively.^[7,8] In our case, restrictive physiology in the left ventricle was also observed with most significant involvement in the right ventricle leading to narrowness in the right ventricular. In addition, the patient had diastolic dysfunction, despite normal left ventricular apex.

Several techniques are available in diagnosis of endomyocardial fibrosis. Transthoracic echocardiography and MRI are very important in its diagnosis. Square roots of the septum and posterior wall in echocardiographic left ventricular involvement and hypercontractile basal segments against obliterated apical regions constitute Merlion findings. Twodimensional (2D) investigation also revealed inversed size of heart chambers and obliterated apical regions. In contrast, the atria were significantly dilated. Restrictive physiology is commonly seen since diastolic functions are consistent with the functional capacity of the patient and patients generally present in the late stage of the disease.^[9] Furthermore, angiographic assessment may not only demonstrate morphological changes in the ventricles due to fibrosis and obliteration, but also reveal hemodynamic findings associated with restrictive cardiomyopathy. In addition, MRI is an important noninvasive technique which is important in the identification of EMF findings. There is a linear relationship between involvement of contrast agent used and increase in inflammatory cells and venous proliferation.^[10] Endomyocardial inflammation and fibrosis can be detected and the degree of systolic dysfunction due to and diastolic dysfunction and restrictive cardiomyopathy can be established by MRI. Organized thrombi and pericardial fluid can also be identified while obliteration

in the ventricular apical region can also be assessed. MRI is also important for differential diagnosis. In our case, we demonstrated increased fibrous in the right ventricular by MRI, which created a gradient. On the other hand, endomyocardial biopsy should only be considered especially in patients whom inadequate results are obtained by the other diagnostic techniques due to the high risk involved, together with the patchy nature of the disease.^[11]

The response to the medical therapy is poor; some symptomatic benefit may be obtained from diuretics whereas the benefit of digital and betablocking agents is considerably limited. These patients should also closely be monitored for the high risk of arrhythmia. Surgical intervention by endocardial decortication may be performed in symptomatic patients with advanced disease and a functional capacity of class IIIIV. However, the perioperative mortality is very high with a rate of 1520%. Endocardioectomy and atrioventricular valve replacement or repair are the most preferred procedures. Severe hemodynamic involvement due to EMF can be repaired by endocardial resection, since the myocardium is not often affected.^[12-14]

Although EMF is rarely seen in Turkey, it should be considered while assessing the cause restrictive cardiomyopathy. The presented case may arouse interest in that increased tissue growth in the right ventricle, led to a 60mmHg gradient due to development of obstruction and subsequent misdiagnosis of idiopathic pulmonary artery hypertension. Patients may be misdiagnosed with IPAH since fibrotic tissue growth and obliteration in the right ventricle can be overlooked. As a result, EMF should also be considered in patients with ventricular obliteration.

REFERENCES

- Hutt MS. Epidemiology aspects of endomyocardial fibrosis. *Postgrad Med J* 1983;59:142-6.
- Uçar O, Gölbaşı Z, Yıldırım N. Two cases of endomyocardial disease with hypereosinophilia in Turkey. *Eur J Echocardiogr* 2005;6:379-81.
- Rutakingirwa M, Ziegler JL, Newton R, Freers J. Poverty and eosinophilia are risk factors for endomyocardial fibrosis (EMF) in Uganda. *Trop Med Int Health* 1999;4:229-35.
- Yılmaz E, Güvenç S, Kocaman O, Kıyan E. Acute severe myocarditis in a woman with hypereosinophilic syndrome. [Article in Turkish] *Türk Kardiyol Dern Arş* 2002;30:265-8.
- Gupta PN, Valiathan MS, Balakrishnan KG, Kartha CC, Ghosh MK. Clinical course of endomyocardial fibrosis. *Br Heart J* 1989;62:450-4.
- Saraçlar M, Özer S, Öztunç F, Çeliker A. Echocardiographic findings in endomyocardial fibrosis. *Turk J Pediatr* 1992;34:47-53.
- Falase AO. Aetiological considerations in Nigeria. In: Valiathan MS, Somers K, Kartha CC, editors. *Endomyocardial fibrosis*. Oxford: Oxford University Press; 1993. p. 88-94.
- Acquatella H, Schiller NB, Puigbó JJ, Gómez-Mancebo JR, Suarez C, Acquatella G. Value of two-dimensional echocardiography in endomyocardial disease with and without eosinophilia. A clinical and pathologic study. *Circulation* 1983;67:1219-26.
- Berensztein CS, Piñeiro D, Marcotegui M, Brunoldi R, Blanco MV, Lerman J. Usefulness of echocardiography and Doppler echocardiography in endomyocardial fibrosis. *J Am Soc Echocardiogr* 2000;13:385-92.
- Aso H, Takeda K, Ito T, Shiraiishi T, Matsumura K, Nakagawa T. Assessment of myocardial fibrosis in cardiomyopathic hamsters with gadolinium-DTPA enhanced magnetic resonance imaging. *Invest Radiol* 1998;33:22-32.
- Somers K, Hutt MS, Patel AK, D'Arbela PG. Endomyocardial biopsy in diagnosis of cardiomyopathies. *Br Heart J* 1971;33:822-32.
- Metras D, Coulibaly AO, Ouattara K. The surgical treatment of endomyocardial fibrosis: results in 55 patients. *Circulation* 1985;72(3 Pt 2):II274-9.
- Metras D. Endomyocardial fibrosis and its surgical treatment: Ivory Coast experience. In: Valiathan MS, Somers K, Kartha CC, editors. *Endomyocardial fibrosis*. Oxford: Oxford University Press; 1993. p. 207-19.
- Valiathan MS, Balakrishnan KG, Sankarkumar R, Kartha CC. Surgical treatment of endomyocardial fibrosis. *Ann Thorac Surg* 1987;43:68-73.